



THE COLLEGE OF  
OPTOMETRISTS

# Stage Two

Overarching case scenario 107

**AGE AND GENDER** Female aged 55 years

**ETHNIC BACKGROUND** Caucasian

**OCCUPATION AND HOBBIES** Nurse in GP practice

**PRESENTING SYMPTOMS AND HISTORY** Feels NV worse recently, even with reading glasses. Struggling to see to administer injections etc. DV still fine. Eyes feel gritty after VDU use and sometimes in the evenings – not able to enjoy reading in the evening as used to.

**GENERAL HEALTH AND MEDICATION** Good. Tamoxifen for past 2 years, following L mastectomy.

**VISION** R6/6+2 L6/9-1

**CURRENT Rx and VA** R +1.50DS L +1.50/-0.25x180 reads N5 just at 40cm binocularly.

**REFRACTION** R +0.25DS L plano / -0.25x180 Add +2.00DS

**VA Distance** RE 6/5 LE 6/7.5-1  
**Near** N5 comfortable from 30-45cm

**BINOCULAR STATUS** cover test with Rx: distance orthophoria near very small XOP, quick recovery

**MOTILITY** full in all directions of gaze, no diplopia or discomfort

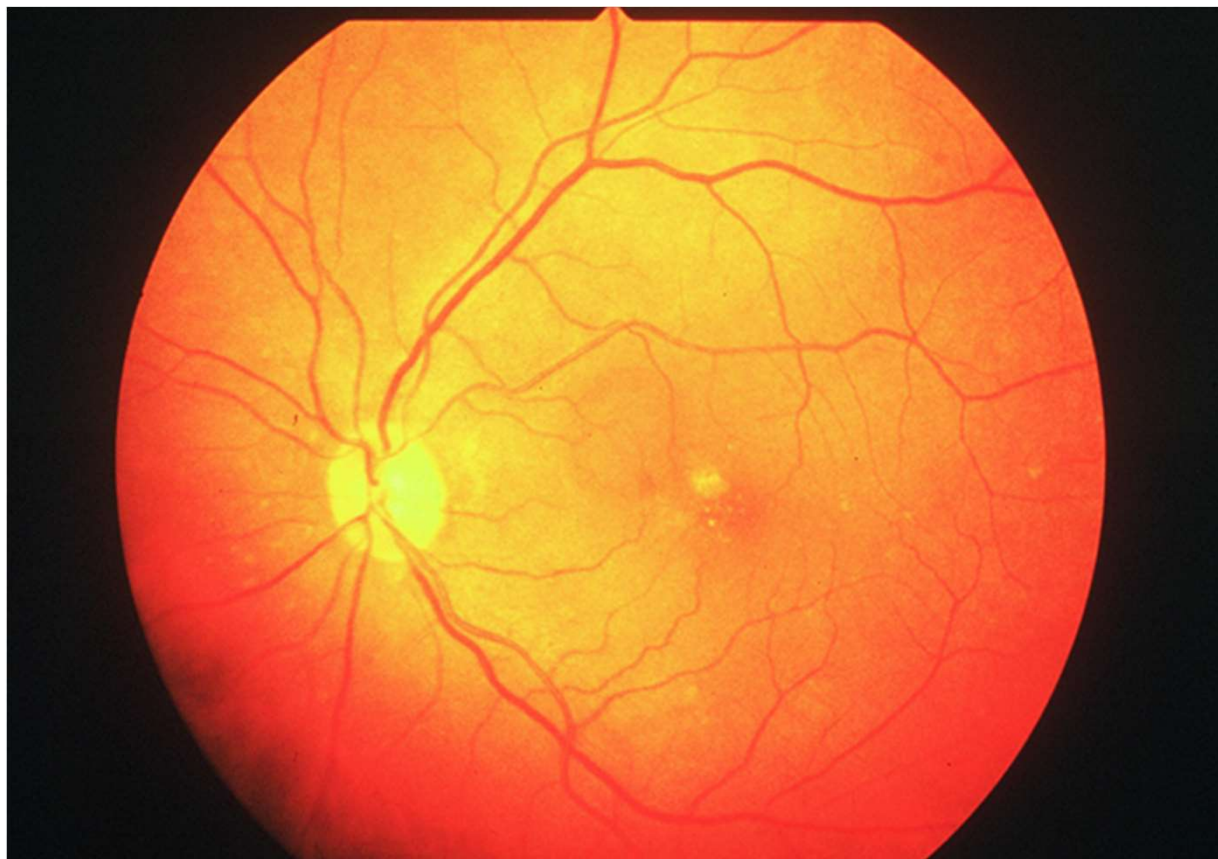
**PUPIL REACTIONS** Direct, consensual and near reflexes all seen

**FUNDUS EXAMINATION** RE healthy fundus LE see fundus image

**EXTERNAL EYE EXAMINATION** corneae clear, conjunctival drying with inferior conjunctival folds. Reduced tear prism and low TBUT (2 secs) R&L.

**IOP:** R16 L15 mmHg using Perkins at 10.00am

# Fundus Image LE



R107